

A prospective, randomized trial of thrombin versus cyanoacrylate injection in the control of acute gastric variceal hemorrhage

Authors

Gin-Ho Lo^{1,3}, Chih-Wen Lin^{1,2,3}, Chi-Ming Tai^{1,2}, Daw-Shyong Perng^{1,2}, I-Lin Chen¹, Jen-Hao Yeh^{1,2,3}, Hui-Chen Lin¹

Institutions

- 1 Department of Medical Research, Division of Gastroenterology, E-DA Hospital, Kaohsiung, Taiwan
- 2 Division of Gastroenterology, E-DA Hospital, Da-Chung Branch, Kaohsiung, Taiwan
- 3 School of Medicine for International Students, I-Shou University, Kaohsiung, Taiwan

submitted 29.8.2019

accepted after revision 10.2.2020

Bibliography

DOI <https://doi.org/10.1055/a-1127-3170>

Published online: 14.4.2020 | Endoscopy 2020; 52: 548–555

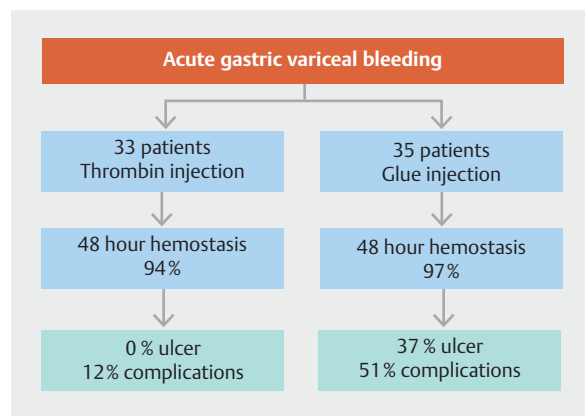
© Georg Thieme Verlag KG Stuttgart · New York

ISSN 0013-726X

Corresponding author

Gin-Ho Lo, MD, Department of Medical Research, E-DA Hospital, 1 Yi-Da Road, Kaohsiung 824, Taiwan
 Fax: +886-7-6150940
ghlo@kimo.com

GRAPHICAL ABSTRACT



Scan this QR-Code for the author commentary.



ABSTRACT

Background Acute gastric variceal hemorrhage (AGVH) is a serious complication of portal hypertension. Endoscopic cyanoacrylate glue injection is standard therapy for acute hemostasis; however, it may be associated with serious complications. The role of thrombin injection has not been confirmed. This study compared endoscopic thrombin and glue injections in the hemostasis of AGVH.

Methods 68 eligible patients with AGVH were randomized to receive thrombin injection (33 patients) or glue injection (35 patients). The primary end point was injection-induced gastric ulcers. Secondary end points were acute hemostasis, rebleeding, and mortality within 42 days.

Results Both groups had comparable baseline data. Hemostasis of active bleeding at endoscopy was 90.0% (9/10) in the thrombin group and 90.9% (10/11) in the glue group ($P=0.58$), and 48-hour hemostasis was achieved in 93.9% (31/33) and 97.1% (34/35), respectively ($P=0.60$). Treatment failure at 5 days occurred in two patients (6.1%) in the thrombin group and two patients (5.7%) in the glue group ($P>0.99$). Gastric ulcers occurred in none of the thrombin group and 11/30 (36.7%) of the glue group ($P<0.001$, 95% confidence interval [CI] 8%–27%). Complications occurred in 4 (12.1%) and 18 (51.4%) patients in the thrombin and glue groups, respectively ($P<0.001$, 95%CI 22%–45%). Two patients who received glue had post-treatment gastric ulcer bleeding. One patient in each group died.

Conclusions Endoscopic thrombin injection was similar to glue injection in achieving successful hemostasis of AGVH. However, a higher incidence of complications may be associated with glue injection.

Clinical.Trials.gov

NCT01717612

TRIAL REGISTRATION: Single-Center, randomized, prospective trial NCT01717612 at clinicaltrials.gov

Introduction

Acute gastric variceal hemorrhage (AGVH) is a catastrophic complication of portal hypertension. The prevalence of gastric varices in patients with portal hypertension is reported to be about 25% [1] and the incidence of AGVH is half that of esophageal varices [2]. AGVH usually results in more severe hemorrhage and higher mortality than esophageal variceal bleeding [3]. Initial therapies for AGVH, including resuscitation, vasoconstrictors, and prophylactic antibiotics, are similar to those for esophageal variceal bleeding [4, 5].

Endoscopic therapy plays a pivotal role in the cessation of gastroesophageal variceal hemorrhage [5, 6]. Endoscopic cyanoacrylate glue injection has been widely recommended for the therapy of AGVH [4, 7–10]. The rate of hemostasis with glue injection ranges from 87% to 100% [11]. However, glue injection may be associated with complications such as ulcer bleeding and systemic thromboembolism with fatality [12]. Alternatively, thrombin injection has also appeared to be highly efficacious for hemostasis of AGVH [11, 13–17]. The advantage of thrombin injection is safety, without inducing ulcers or embolism [13–17]. Controlled studies between glue injection and thrombin injection have not yet been reported. Thus, we conducted a trial aimed to compare the relative safety and efficacy between endoscopic thrombin and glue injection in the cessation of AGVH.

Methods

Patients

Between October 2012 and March 2018, patients with a history of portal hypertension and presenting with hematemesis or tarry stool were considered for enrollment. The trial was carried out at an academic medical center with 1200 beds (E-Da Hospital, Taiwan).

Inclusion criteria were as follows: 1) the etiology of portal hypertension was cirrhosis; 2) age 20–80 years; 3) AGVH was confirmed on emergency endoscopy within 12 hours. Cirrhosis was diagnosed by history, physical findings, ultrasound or computed tomography, or previous histological findings. AGVH was defined as: 1) when blood was seen directly on endoscopy to issue from a gastric varix; or 2) stigmata of recent hemorrhage such as blood clots coating the gastric varices or the presence of hematocystic spots or white nipples on gastric varices, in the absence of esophageal variceal bleeding or other source of bleeding [7, 16]. Exclusion criteria were as follows: 1) association with severe systemic illness, such as sepsis, cerebral vascular accident, chronic obstructive pulmonary disease, advanced carcinoma, hepatocellular carcinoma (Barcelona Club Liver Cancer class C or D); 2) presence of massive ascites; 3) serum creatinine >3 mg/dL, hepatic encephalopathy >stage II; 4) serum bilirubin >10 mg/dL; 5) moribund patients (expected life expectancy <1 month); 6) Child–Pugh score >13; 7) pregnancy; 8) esophageal variceal bleeding; 9) with ulcers on gastric varices or history of previous glue injection, sclerotherapy, band ligation on gastric varices within 3 months; 10) patient was uncooperative or declined to be enrolled.

Eligible patients were randomized immediately after emergency endoscopy had confirmed gastric variceal bleeding. The method of randomization was based on opaque-sealed envelopes numbered according to a table of random number. Eligible patients were randomized by a coordinator to one of two groups: thrombin group or glue group. The thrombin group was treated with endoscopic thrombin injection and the glue group received endoscopic glue injection.

Endoscopic therapy

Premedication of 20 mg of butyl scopolamine bromide was given intramuscularly prior to endoscopic procedures in both groups. The injection site for endoscopic therapy was aimed at the bleeding point of the varices.

In the thrombin group, the injected agents consisted of 5 mL lyophilized human thrombin in calcium chloride solution containing thrombin 500 IU/mL (Flo seal; Baxter Healthcare Corporation, CA, Hayward, USA). Olympus 23-gauge injection needles were used to inject the solution into varices. During each session, only 5 mL of thrombin solution was injected at one site. After injection, the needle was retracted and the injection device sheath was applied to tamponade the varix for about 1 minute [17]. If the variceal bleeding could not be controlled by one injection, a second dose of 5 mL thrombin solution was injected. In both groups, if active gastric variceal bleeding persisted despite two injections, another injection of glue was allowed to stop the bleeding.

For the glue group, our technique of endoscopic obturation of gastric varices by glue injection has been described previously [7]. Briefly, one injection consisted of 0.5 mL n-butyl-2-cyanoacrylate (Histoacryl; B. Braun Surgical, Rubi, Spain) mixed with 1 mL Lipiodol ultra-fluide (Guerbet, Bois Cedex, France). Olympus single-use 20-gauge injectors were used to inject the solution. The needles were withdrawn soon after injection. Up to three injections were allowed if bleeding continued or huge varices were noted.

After completion of either thrombin or glue injection, the injectors were loaded with 0.7 mL of saline to flush residual therapy solution into the varices. All endoscopic procedures were performed by experienced endoscopists with at least 2 years' experience and more than five endoscopic procedures for gastric variceal bleeding.

Classification of gastric varices and severity of liver disease

Based on Sarin's classification [3], gastric varices were classified as gastroesophageal varices type 1 and type 2 (GOV1, GOV2), and isolated gastric varices type 1 and type 2 (IGV1, IGV2). GOV1 are gastric varices in continuity with esophageal varices and extend 2–5 cm below the gastroesophageal junction. GOV2 are gastric varices extending to the fundus of the stomach. IGV1 are isolated gastric varices located in the fundus. IGV2 are isolated gastric varices locating in the gastric body and antrum. The sizes of esophageal varices were based on Beppu's classification and the sizes of gastric varices were based on Hashizume's classification [18]. The severity of liver disease was based on the Child–Pugh classification [19] and

Model for End-stage Liver Disease (MELD) score, and was evaluated at admission.

Supportive therapy

Standard therapy, including blood and frozen plasma transfusion, fluid, albumin and electrolyte replacement, and lactulose was administered to patients of both groups as clinically indicated. Prophylactic antibiotics using cefazolin were given to all patients for 5 days. Terlipressin (Glypressin, Ferring AB, Malmö, Sweden) was started at 2 mg intravenous bolus injection, and then 1 mg every 6 hours for 3 days. Hemoglobin and hematocrit were measured at presentation of acute bleeding, after endoscopic examination, and then daily for 5 days. Blood transfusion was aimed at maintaining hemoglobin ≥ 8 g/dL. The volume of blood transfused prior to endoscopic examination and 5 days after endoscopic therapy was recorded.

Follow-up treatment

After acute hemostasis for 5 days, carvedilol 6.25 mg twice a day was instituted to prevent rebleeding [20]. All patients were scheduled to undergo repeat endoscopy 4–5 weeks after hemostasis to detect ulcers on gastric varices, and band ligation of prominent esophageal varices was performed if patients agreed. Proton pump inhibitors were administered for 8 weeks among patients noted to have ulcers. Patients in both groups with residual prominent gastric varices were advised to have glue injection at intervals of 8 weeks or transjugular intrahepatic portosystemic stent shunt (TIPS) [21] for prevention of chronic rebleeding. Individuals with hepatitis B or C virus cirrhosis were given oral antiviral drugs if possible. Patients with alcoholism were advised to abstain from drinking alcohol.

Informed consent was obtained from all enrolled patients. The study was approved by the Ethics Committee of E-DA Hospital (EMRP38101N). The study protocol was performed in accordance with the ethical guidelines of the 1975 Helsinki Declaration.

Definitions

Treatment failure was defined as failure to control acute bleeding episodes or very early rebleeding or death within 5 days. Failure to control acute variceal bleeding was based on the modified criteria of the Baveno consensus III [22,23]. Very early rebleeding was defined when criteria for failure to control acute variceal bleeding occurred between 48 and 120 hours after enrollment in patients who had initial hemostasis of acute bleeding. Initial hemostasis was defined as when criteria for failure did not occur within 48 hours of enrollment. The 5-day hemostasis was defined when criteria for failure to control acute variceal bleeding and very early rebleeding did not occur within 5 days of enrollment. Failure to control acute bleeding and very early rebleeding were assessed by two experienced clinicians. Patients in whom initial hemostasis failed or who experienced very early rebleeding were treated with vasoconstrictor, balloon tamponade, repeat endoscopic therapy or TIPS, as clinically indicated.

Complications

Complications in both groups were recorded, including fever $>38^{\circ}\text{C}$ without infection, bacterial infections, thromboembolism, ulcers on gastric varices, ulcer bleeding, and post-therapy abdominal pain requiring analgesics. The sizes of gastric ulcers were determined by two experienced endoscopists. The estimation of ulcer size was based on an open 4.6-mm biopsy forceps (FlexiBite; Medi-Globe, Achenmuhle, Germany) and only an ulcer ≥ 5 mm was included in the analysis.

Outcomes

The primary end point was the development of ulcers on the gastric varices induced by glue or thrombin injection at 6 weeks. Secondary end points included initial hemostasis, rebleeding, all post-therapy complications, the amount of blood transfused, and mortality within 6 weeks. The endoscopists assessing the severity of ulcers were blinded to prior endoscopic therapy.

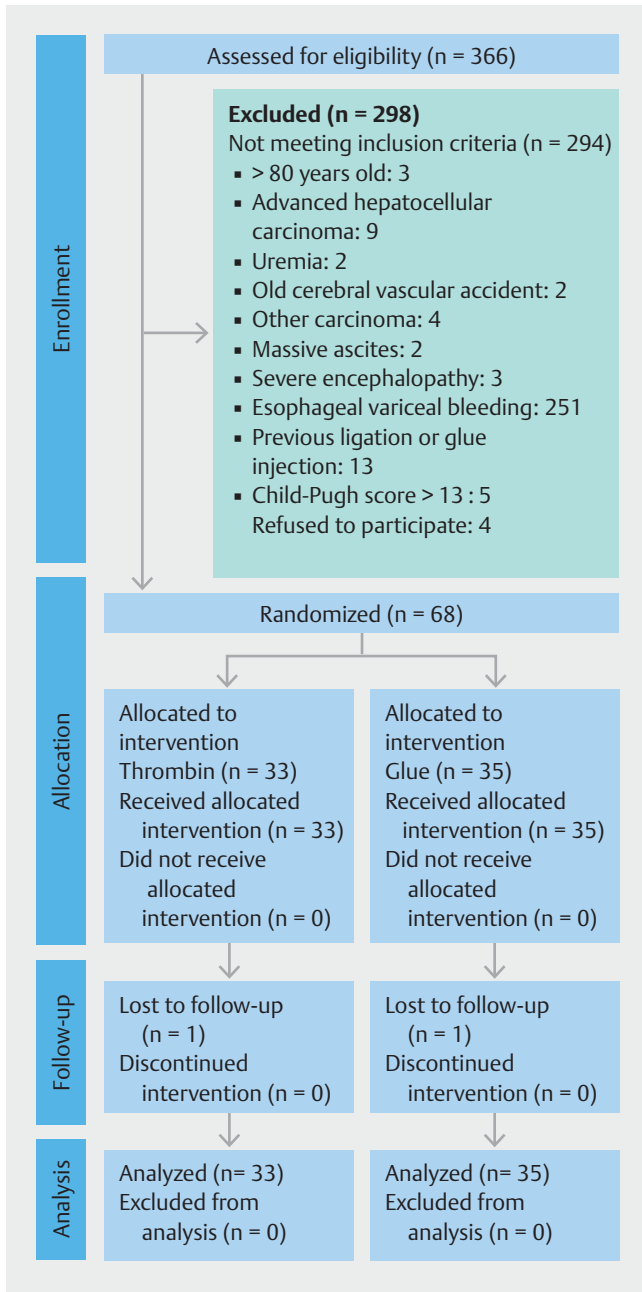
Statistical analysis and sample size calculation

The data were expressed as mean with standard deviation (SD). Statistical analysis was based on an intention-to-treat principle. Quantitative variables were compared according to Student's *t* test, and qualitative variables were compared using the chi-squared test and Fisher's exact test when appropriate. The Kaplan–Meier estimation was applied to examine the time to first occurrence of recurrent bleeding from gastric varices. The Log rank test was used to examine the variation of rebleeding episodes. Two-sided 95% confidence intervals (CIs) were calculated for the proportions of hemostasis and complications for each arm separately using the Clopper–Pearson method. All *P* values were two-tailed and a *P* value of <0.05 was considered significant. Analyses were performed using IBM SPSS statistics 24 software (IBM Corp., Armonk, New York, USA).

We presumed that the incidence of gastric ulcers induced by thrombin and glue injections were 0% [13–17] and 20% [12], respectively. A sample size of 62 patients was required to detect the difference with a two-tailed test to achieve a beta value of 0.2 and an α error of 5%. If 10% of patients were lost to follow-up, a total of 68 patients were required.

Results

A total of 366 patients were screened for eligibility and 298 individuals were excluded, mainly because they had esophageal variceal bleeding (► Fig. 1). Finally, 68 eligible patients were enrolled, 33 patients in the thrombin group and 35 patients in the glue group. Both groups were comparable in terms of baseline data such as etiology of cirrhosis, severity of liver disease, variceal size, active bleeding at endoscopy, and classification of gastric varices; however, the volume of blood transfused was significantly higher in the thrombin group than in the glue group (► Table 1). Alcoholism and hepatic encephalopathy were more frequent in the thrombin group, with marginal significance. Among both treatment groups, GOV1 was the most common type of gastric varices, followed by GOV2.



► **Fig. 1** Trial profile.

► **Table 2** shows the treatment outcomes. The mean volume of thrombin and glue was 5.1 mL and 1.8 mL, respectively. Active variceal bleeding was encountered in 10 patients in the thrombin group and 11 patients in the glue group. Hemostasis of active bleeding was achieved in 90.0% (9/10) of the thrombin group and in 90.9% (10/11) of the glue group ($P=0.58$). Hemostasis failed in one patient from each group. In the thrombin group, the patient (IGV1) was rescued by repeat thrombin injection, whereas in the glue group, the patient (GOV2) received balloon tamponade and repeat glue injection the following day. Initial hemostasis for 48 hours was 93.9% (31/33) in the thrombin group and 97.1% (34/35) in the glue group ($P=$

► **Table 1** Baseline data of both groups.

	Thrombin (n=33)	Glue (n=35)
Age, mean (SD), years	54.1 (13.0)	55.9 (14.0)
Female/male, n	9/24	8/27
Etiology of cirrhosis, n (%)		
Alcoholism	17 (51.5)	9 (25.7)
Hepatitis B	4 (12.1)	9 (25.7)
Hepatitis C	9 (27.3)	10 (28.6)
Cryptogenic, n (%)	3 (9.1)	7 (20.0)
AST, mean (SD), U/L	95.9 (109.3)	65.3 (42.3)
ALT, mean (SD)	50.2 (55.6)	42.8 (31.1)
Albumin, mean (SD), gm/dL	3.3 (0.6)	3.3 (0.6)
Bilirubin, mean (SD), gm/dL	2.4 (2.1)	1.86 (1.3)
Prolonged prothrombin time, mean (SD), seconds	2.5 (1.6)	2.9 (2.2)
Creatinine, mean (SD), mg/dL	1.1 (0.3)	1.3 (0.5)
Ascites present, n (%)	8 (24.2)	15 (42.9)
Encephalopathy, n (%)	10 (30.3)	4 (11.4)
Child – Pugh score		
Mean (SD)	6.7 (1.9)	7.4 (2.0)
A/B/C, n	18/11/4	15/11/9
MELD score, mean (SD)	12.3 (6.2)	11.4 (3.0)
Hemoglobin, mean (SD), gm/dL	9.0 (2.4)	8.9 (2.3)
Size of EV, F1/F2/F3, n	9/15/3	8/21/2
Size of GV, F1/F2/F3, n	3/17/13	3/24/8
Prior history of variceal bleed, EV/GV, n	9/5	12/4
Classification of GV, n		
GOV1	15	17
GOV2	12	14
IGV1	6	4
Association with HCC, n (%)	5 (15.2)	7 (20.0)
Active bleed at endoscopy, n	10	11
Hypovolemic shock at entry, n	6	6
Blood transfusion prior to endoscopy, mean (SD), units	5.2 (4.6)	3.3 (2.2)

SD, standard deviation; AST, aspartate aminotransferase; ALT, alanine aminotransferase; MELD, Model for End-Stage Liver Disease; EV, esophageal varices; GV, gastric varices; F1, linear varices; F2, tortuous, nodular varices; F3, tumor-like varices; GOV1, gastroesophageal varices, type 1; GOV2, gastroesophageal varices, type 2; IGV1, isolated gastric varices, type 1; HCC, hepatocellular carcinoma.

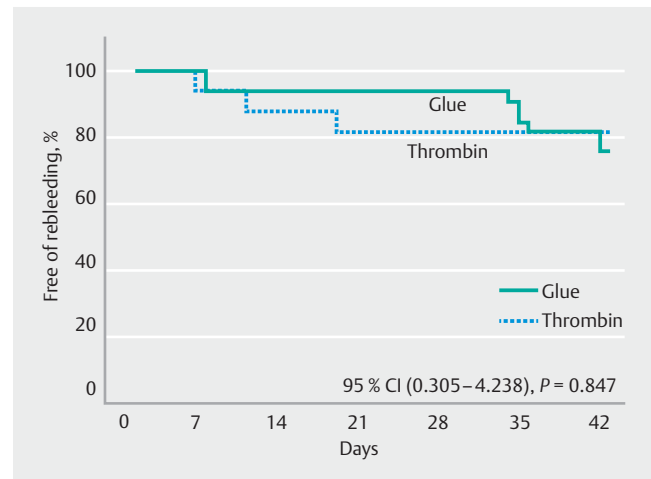
All variables showed no significant difference between both groups, except for volume of blood transfused ($P < 0.04$).

► **Table 2** Main outcomes in the two treatment groups.

	Thrombin (n = 33)	Glue (n = 35)	P
Volume, mL			
▪ Mean (SD)	5.1 (0.5)	1.8 (0.2)	
▪ Range	5.0–10.0	1.5–3.0	
Hemostasis of active bleeding, n/N (%)			
▪ GOV1	2/2	3/3	0.58
▪ GOV2	6/6	5/6	
▪ IGV1	1/2	2/2	
Initial hemostasis for 48 hours, n (%)			
	31 (93.9)	34 (97.1)	0.60
Very early rebleeding (3–5 days), n			
	0	1	>0.99
Treatment failure (5 days), n (%)			
▪ GOV1	0/15 (0)	0/17 (0)	>0.99
▪ GOV2	2/12 (16.7)	1/14 (7.1)	
▪ IGV1	0/6 (0)	1/4 (25)	
Rebleeding between 6–42 days, n			
	3	4	0.67
Source of rebleeding, n			
▪ Esophageal varices	1	2	>0.99
▪ Gastric varices	2	0	0.23
▪ Ulcer bleed	0	2	0.49
Gastric variceal obliteration, n (%)			
	2 (6.1)	7 (20.0)	0.15
Hospital stay, days			
▪ Mean (SD)	8.2 (11.0)	7.6 (3.7)	0.76
▪ Range	3–22	2–27	
Blood transfusion after endoscopy, units			
			0.72
▪ Mean (SD)	1.8 (2.2)	2.0 (2.7)	
▪ Range	0–15	0–18	
30-day mortality, n (%)			
	0 (0)	1 (2.9)	>0.99

SD, standard deviation; GOV1, gastric varices, type 1; GOV2, gastric varices, type 2; IGV1, isolated gastric varices.

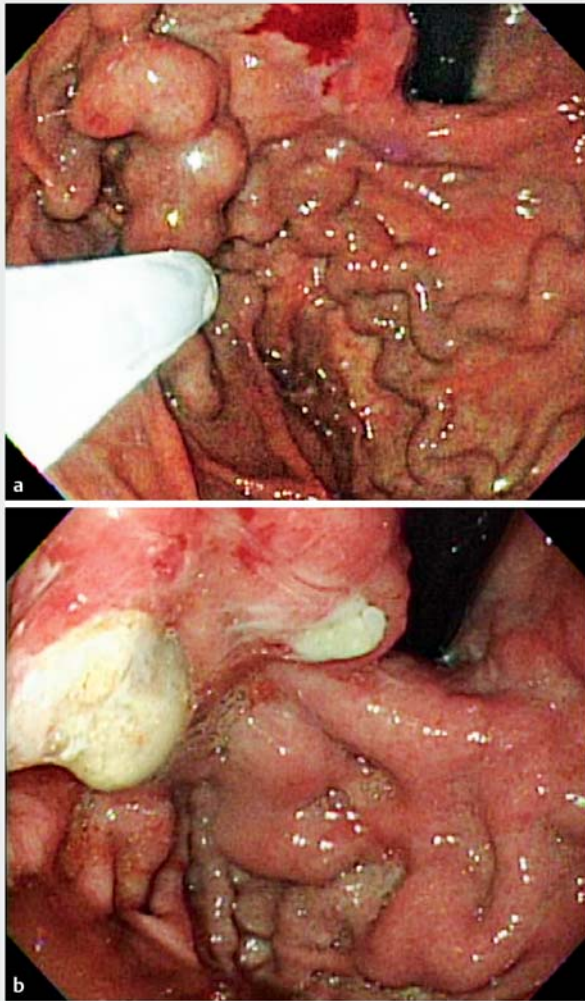
0.60). The one case of hemostatic failure in the thrombin group continued to bleed after reinjection of thrombin and was rescued by glue injection. The patient in the glue group re-bleed 3 days after initial hemostasis; he refused TIPS and received balloon tamponade followed by a second session of glue injection, which was unsuccessful. The patient died of sepsis. Thus, treatment failure at 5 days was 6.1% in the thrombin group and 5.7% in the glue group ($P > 0.99$). The failure rate was 0% in GOV1 pa-

► **Fig. 2** Probability of being free of rebleeding from gastric varices.

tients in both groups. The failure rate among GOV2 patients was 16.7% in the thrombin group and 7.1% in the glue group ($P = 0.58$). Among patients with IGV1, hemostasis failed in only one of four patients in the glue group and none of the six patients in the thrombin group ($P = 0.40$).

Gastric variceal rebleeding between 6 and 42 days after index bleeding occurred in two patients in the thrombin group (► **Table 2**). One patient was treated with reinjection of thrombin and the other patient was rescued by glue injection. Two patients in the glue group had ulcer bleeding from the gastric varices. Both patients were successfully treated with thrombin injection. Band ligation of esophageal varices was performed in 12 patients of the thrombin group and 15 patients of the glue group at follow-up endoscopy. Esophageal variceal bleeding was encountered in one patient in the thrombin group and two patients in the glue group. All three patients were successfully treated by band ligation. Cumulative rebleeding from gastric varices is shown in ► **Fig. 2** ($P = 0.85$). Gastric variceal obliteration at second endoscopy, about 5 weeks after therapy, was slightly higher in the glue group; however, this difference was not statistically significant.

Injection-induced gastric ulcers on gastric varices were noted in 11 of 30 patients (36.7%) in the glue group who underwent endoscopic follow-up (► **Fig. 3**), whereas no patients were recorded with ulcers in the 29 patients in the thrombin group who underwent endoscopic follow-up ($P < 0.001$, 95%CI 8%–27%). The size of ulcers on gastric varices ranged from 5 mm to 20 mm. All complications during the 6-week study period are shown in ► **Table 3**. The incidence of complications was higher in patients receiving glue injection than in those having thrombin injection ($P < 0.001$, 95%CI 22%–45%). Three patients in the thrombin group and five patients in the glue group refused endoscopic follow-up. One patient in the thrombin group was lost to follow-up at 28 days and one patient in the glue group was lost to follow-up at 35 days after enrollment. Abdominal pain was recorded in one patient in the thrombin group and four patients in the glue group ($P = 0.35$). No systemic thromboembolism occurred in either group during the study



► **Fig. 3** Glue injection therapy. **a** Use of glue to stop acute gastric variceal bleeding. **b** Gastric ulcers after glue injection.

period. Two patients died during the 6-week study period. One patient in the glue group experienced hemostasis failure and died of sepsis at 10 days after enrollment and the other patient in the thrombin group died of hepatocellular carcinoma at 38 days after enrollment. There was no difference in hospitalization days, mortality, and post-therapy volume of blood transfused between the two therapy groups. If injection-induced ulcers were excluded, 4 patients in the thrombin group and 11 patients in the glue group had complications; the difference was only marginally significant ($P=0.053$).

After hemostasis, 24/33 patients (72.7%) in the thrombin group and 23/34 patients (67.6%) in the glue group agreed to undergo elective glue injections to achieve variceal obliteration.

Discussion

AGVH is a dismal event of portal hypertension, with a mortality rate of up to 45% reported in the early 1990s [3]. Among various modalities, surgery and sclerotherapy have been largely

► **Table 3** Adverse events of both groups over the 6-week study period.

	Thrombin (n = 33)	Glue (n = 35)	P value
Total complications, n (%) ¹	4 (12.1)	18 (51.4)	<0.001
Gastric ulcers, n (%) ²	0 (0)	11 (36.7)	<0.001
▪ 5–9 mm	0	5	
▪ 10–14 mm	0	2	
▪ ≥15 mm	0	2	
Fever, n	2	3	>0.99
Ulcer bleeding, n	0	2	0.49
Bacteremia/ sepsis, n	0	2	0.49
Abdominal pain, n	1	4	0.35
UTI, n	1	1	0.60
SBP, n	0	1	>0.99

UTI, urinary tract infection; SBP, spontaneous bacterial peritonitis.

¹ 4 patients had more than one complication.

² Only 29 patients in the thrombin group and 30 patients in the glue group underwent endoscopic follow-up. Two of the patients also had ulcer bleeding.

abandoned owing to high complication and rebleeding rates [5, 7, 23, 24]. Band ligation is recommended by guidelines to treat GOV1 varices, whereas TIPS and balloon-occluded retrograde transvenous obliteration, owing to the requirement for special expertise, are usually indicated for refractory bleeding or secondary prevention [5, 11, 21].

Endoscopic therapy with either cyanoacrylate glue or thrombin injection has been employed for decades to treat AGVH [13, 25]. Owing to the superiority of hemostasis, glue injection is now recommended by all practice guidelines as standard therapy for the control of AGVH, especially GOV2 and IGV1 varices [8–10]. However, glue injections may be associated with several complications, such as ulceration in up to 65% [22], bacteremia in up to 32% [26], and systemic embolization in 4.4% [27]. Asymptomatic embolism detected by imaging has been recorded in up to 47% [28]. Moreover, several fatalities from distant embolism in brain, atrium, lung, and spleen have occurred after glue injection [12]. This implies that, although glue injection is highly effective for hemostasis, safety remains an issue of serious concern.

Thrombin has also been shown to be effective in the hemostasis of AGVH [13]. The mechanism of hemostasis induced by thrombin is through the conversion of fibrinogen to fibrin and enhancement of platelet aggregation. A 5-mL solution containing 5000 units of thrombin is reported to clot a liter of blood within 60 seconds [11]. The benefits of thrombin injection include safety, without inducing ulcers or distant thrombosis. Moreover, thrombin injection is very simple and easy to administer, without causing the damage to equipment that may be associated with glue injection [11]. Previous studies used bovine thrombin, which may lead to a concern of eliciting prion disease [13, 14, 16]; however, bovine thrombin has now been

replaced by human thrombin. The acute hemostasis rate of AGVH by injection of thrombin ranges from 65% to 100%, without significant adverse events [1, 15, 17]. Our mean dose of thrombin in each patient was 2550 IU, higher than the dose of 1100 IU adopted by Smith et al. [17]. This may partly explain why the 5-day hemostasis rate was up to 94% in the current study compared with 65% in the Smith trial.

Complications, including ulcers and other adverse events, occurred significantly more frequently in patients receiving glue injection than in those receiving thrombin injection. Gastric ulcers were noted in 36.7% of patients receiving glue injection. This incidence was slightly higher than the 19% reported by Choudhuri et al. [29], but lower than the figure of 65% reported by Sarin [23]. Post-therapy ulcers usually heal after therapy, but ulcer bleeding, chronic huge ulceration, and sepsis may occur and be difficult to treat [7, 30]. Consistent with previous series [13–17], thrombin did not induce mucosal ulceration in the current study. Interestingly, two patients in the glue group with ulcer bleeding were rescued by thrombin injection. This implies that thrombin could avoid the development of ulcers induced by repeated glue injection. Imaging studies of systemic embolism were not performed in the current study. Fortunately, no case of distant embolism occurred in either group. Mortality was appreciably low in both study arms. This could be due to a low proportion of Child–Pugh class C patients and observation for only 6 weeks. However, this could also be ascribed to the high efficacy of both therapies in the control of AGVH, as shown in a report from the UK of only 2.7% mortality after median follow-up of 22 months [16].

Our controlled study proved that thrombin injection compared with glue injection in the therapy of AGVH has the advantage of fewer complications, fewer ulcers, and similar efficacy of hemostasis. However, there are a few shortcomings of the current study. First, the sample size was small. The study was designed to compare the adverse events. A much larger sample size is required to compare the difference in acute hemostasis. Second, the trial aimed to assess the safety and efficacy in the short term. Compared with glue injection, human thrombin is much more expensive. Long term safety, efficacy, and cost-effectiveness require further investigation. Our previous trial showed that TIPS was superior to endoscopic therapy with glue injection in the prevention of gastric variceal rebleeding [7]. Thrombin injection could be a good bridge to more definitive therapy such as TIPS.

In conclusion, our controlled trial of endoscopic thrombin injection and glue injection in the management of AGVH confirmed the high safety profile of thrombin injection. In addition, both therapies achieved similarly high efficacy in acute hemostasis.

Funding

E-DA Hospital EDPJ 99019

Acknowledgements: The study was sponsored by a grant from E-DA Hospital (EDPJ 99019).

Competing interests

The authors declare that they have no conflict of interest.

References

- [1] Sarin SK, Primignani M, Agarwal SR. Gastric varices. In: de Franchis R ed. Portal hypertension III. Proceedings of the third Baveno International Consensus Workshop on definitions, methodology and therapeutic strategies. Oxford: Blackwell Science; 2001: 76–96
- [2] Tripathi D, Hayes PC. Endoscopic therapy for bleeding gastric varices: to clot or glue? *Gastrointest Endosc* 2008; 68: 883–886
- [3] Sarin SK, Lahoti D, Saxena SP et al. Prevalence, classification and natural history of gastric varices: a long-term follow-up study in 568 portal hypertension patients. *Hepatology* 1992; 16: 1343–1349
- [4] Garcia-Tsao G, Bosch J. Management of varices and variceal hemorrhage in cirrhosis. *New Engl J Med* 2010; 362: 823–832
- [5] Garcia-Pagan JC, Barrufet M, Cardenas A et al. Management of gastric varices. *Clin Gastroenterol Hepatol* 2014; 12: 919–928
- [6] Lo GH. Endoscopic treatment for portal hypertension. *Hepatol Int* 2018; 12 : (Suppl. 01): 91–101
- [7] Lo GH, Lai KH, Cheng JS et al. A prospective, randomized trial of butyl cyanoacrylate injection versus band ligation in the management of bleeding gastric varices. *Hepatology* 2001; 33: 1060–1064
- [8] Laine L, Planas R, Nevens F et al. Treatment of acute bleeding episode. In: de Franchis R ed. Portal hypertension IV. Proceedings of the fourth Baveno International Consensus Workshop. Oxford: Blackwell Publishing; 2006: 217–242
- [9] Garcia-Tsao G, Abraldes JG, Berzigotti A et al. Portal hypertensive bleeding in cirrhosis: risk stratification, diagnosis, and management: 2016 Practice Guidance by the American Association for the Study of Liver Diseases. *Hepatology* 2017; 65: 311–335
- [10] Tripathi D, Stanley AJ, Hayes PC et al. UK guidelines on the management of variceal hemorrhage in cirrhotic patients. *Gut* 2015; 64: 1680–1704
- [11] Tripathi D, Ferguson W, Therapondos G et al. Review article: recent advances in the management of gastric varices. *Aliment Pharmacol Ther* 2006; 24: 1–17
- [12] Al-Hillawi L, Wong T, Tritto G et al. Pitfalls in histoacryl glue injection therapy for esophageal, gastric and ectopic varices: a review. *World J Gastrointest Surg* 2016; 8: 729–734
- [13] Williams SG, Peters RA, Westaby D. Thrombin: an effective treatment for gastric variceal hemorrhage. *Gut* 1994; 35: 1287–1289
- [14] Przemioslo RT, McNair A, Williams R. Thrombin is effective in arresting bleeding from gastric variceal hemorrhage. *Dig Dis Sci* 1999; 44: 778–781
- [15] Yang WL, Tripathi D, Therapondos G et al. Endoscopic use of human thrombin in bleeding gastric varices. *Am J Gastroenterol* 2002; 97: 1381–1385
- [16] McAvoy NC, Plevris JN, Hayes PC. Human thrombin for the treatment of gastric and ectopic varices. *World J Gastroenterol* 2012; 7: 5912–5917
- [17] Smith MR, Tidswell R, Tripathi D. Outcomes of endoscopic human thrombin injection in the management of gastric varices. *Eur J Gastroenterol Hepatol* 2014; 26: 846–852
- [18] Philips CA, Sahney A. Oesophageal and gastric varices: historical aspects, classification and grading: everything in one place. *Gastroenterol Rep* 2016; 4: 186–195
- [19] Pugh RNN, Murray-Lyon IM, Dawson JL et al. Transection of esophagus for bleeding esophageal varices. *Br J Surg* 1973; 60: 646–649

- [20] Lo GH, Chen WC, Wang HM et al. A randomized, controlled trial of carvedilol vs. nadolol plus isosorbide mononitrate for the prevention of variceal rebleeding. *J Gastroenterol Hepatol* 2012; 27: 1681–1687
- [21] Lo GH, Liang HL, Chen WC et al. A prospective, randomized controlled trial of transjugular intrahepatic portosystemic shunt vs. cyanoacrylate injection in the prevention of gastric variceal rebleeding. *Endoscopy* 2007; 39: 679–685
- [22] de Franchis R. Updating consensus in portal hypertension: report of the Baveno III Consensus Workshop on definitions, methodology and therapeutic strategies in portal hypertension. *J Hepatol* 2000; 33: 846–852
- [23] Sarin SK, Jain AK, Jain M et al. A randomized controlled trial of cyanoacrylate versus alcohol injection in patients with isolated fundic varices. *Am J Gastroenterol* 2002; 97: 1010–1015
- [24] Takeuchi M, Nakai Y, Syu A et al. Endoscopic ligation of gastric varices. *Lancet* 1996; 348: 1038
- [25] Soehendra N, Nam VC, Grimm H et al. Endoscopic obliteration of large esophagogastric varices with bucrylate. *Endoscopy* 1986; 18: 25–26
- [26] Chen WC, Hou MC, Lin HC et al. Bacteremia after endoscopic injection of N-butyl-2-cyanoacrylate for gastric variceal bleeding. *Gastrointest Endosc* 2001; 54: 214–218
- [27] Prachayakul V, Aswakul P, Cahntararajanisiri T et al. Factors influencing clinical outcomes of histoacryl glue injection-treated gastric variceal hemorrhage. *World J Gastroenterol* 2013; 19: 2379–2387
- [28] Romero-Castro R, Ellrichmann M, Ortiz-Moyano C et al. EUS-guided coil versus cyanoacrylate therapy for the treatment of gastric varices: a multicenter study. *Gastrointest Endosc* 2013; 78: 711–721
- [29] Choudhuri G, Chetri K, Bhat G et al. Long-term efficacy and safety of N-butylcyanoacrylate in endoscopic treatment of gastric varices. *Trop Gastroenterol* 2020; 31: 155–164
- [30] Cheng LF, Wang ZQ, Li CZ et al. Low incidence of complications from endoscopic gastric variceal obturation with butyl cyanoacrylate. *Clin Gastroenterol Hepatol* 2010; 8: 760–766